

15歳 男性

現病歴：学校検診で右頸部腫瘍を指摘。それまで自覚なし。

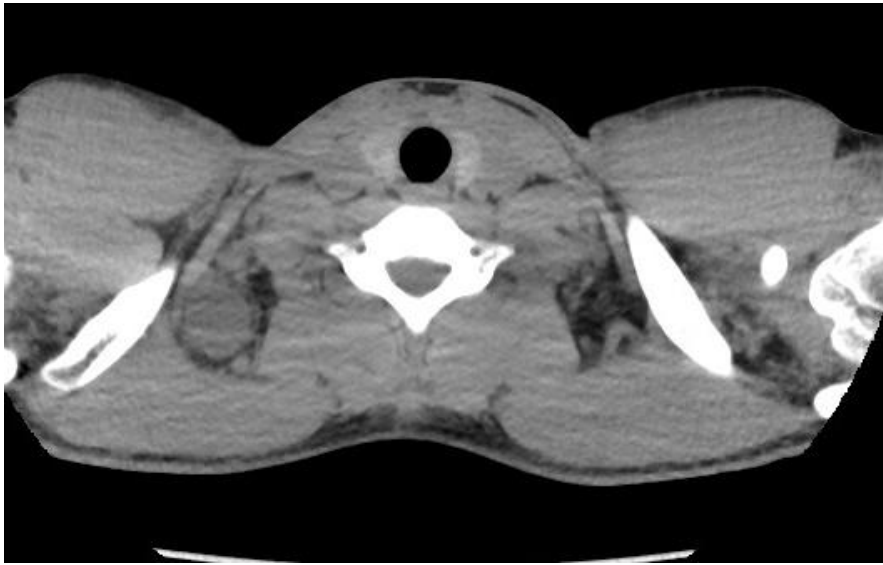現症：弾性硬、圧痛なし、左右方向に可動良好。

既往歴：特記事項なし。

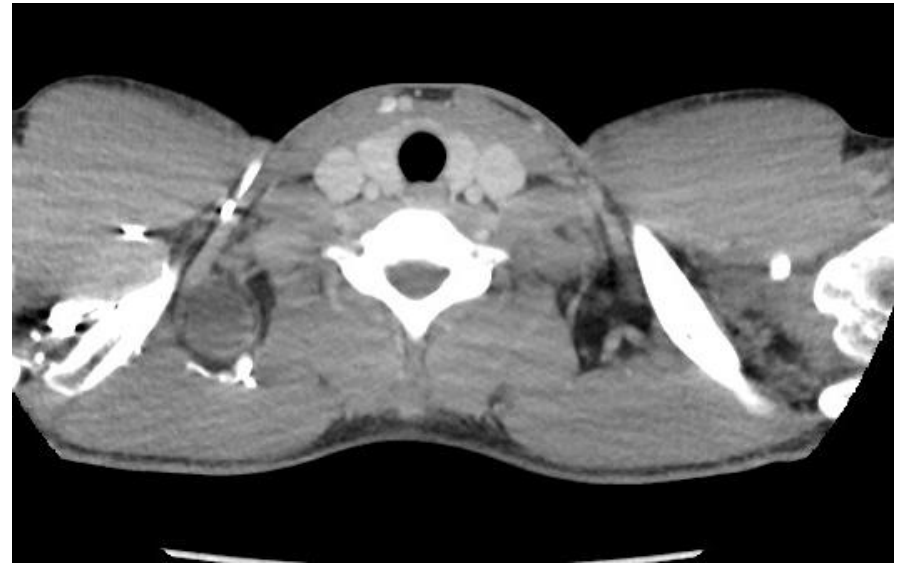
生活歴：特記事項なし。

家族歴：特記事項なし。

CT

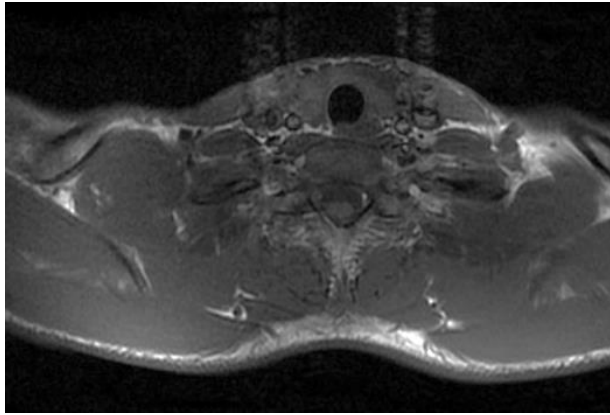


単純CT

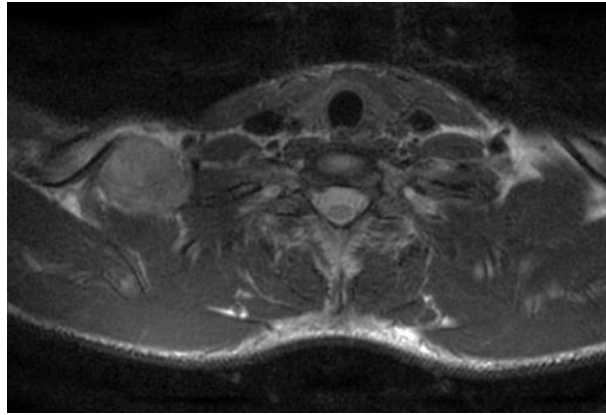


造影CT

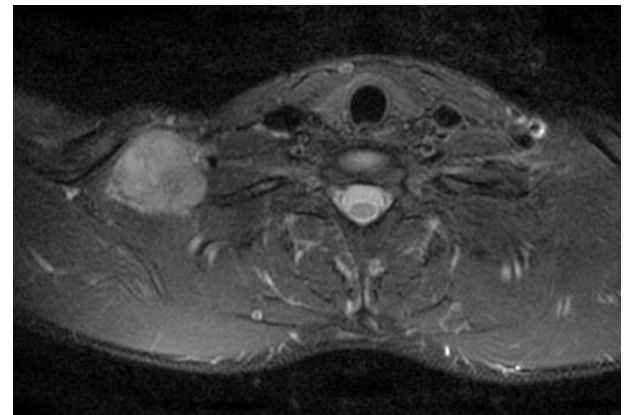
MRI



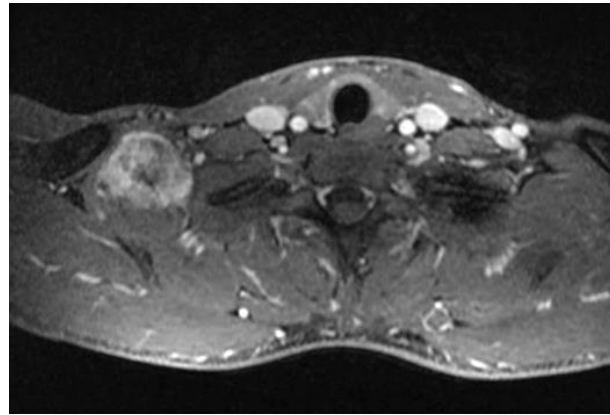
T1WI



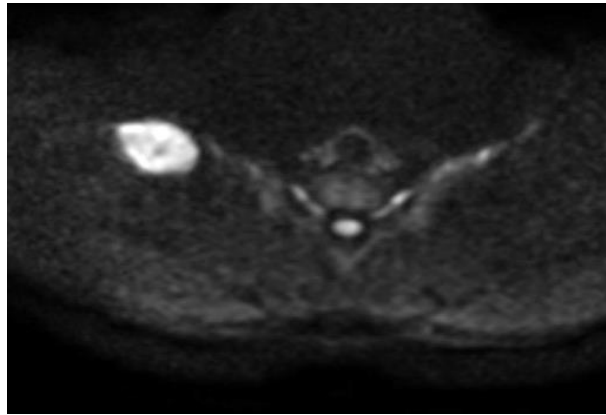
T2WI



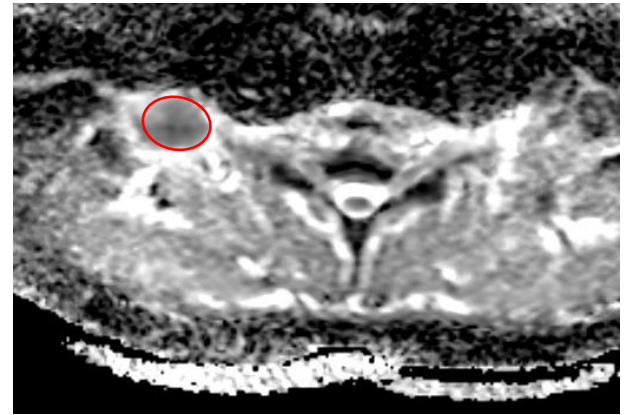
FS-T2WI



FS-Gd T1WI



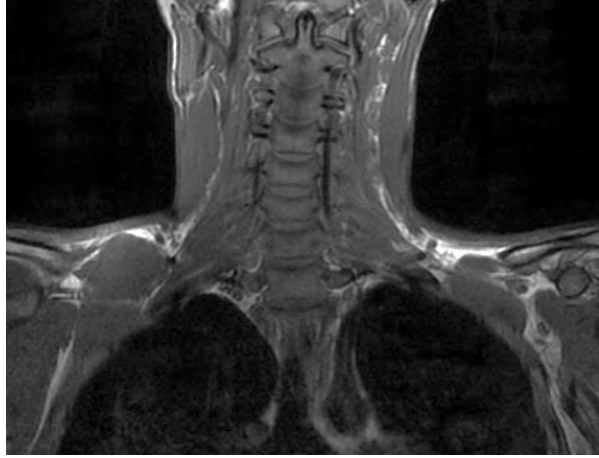
DWI (b=1000)



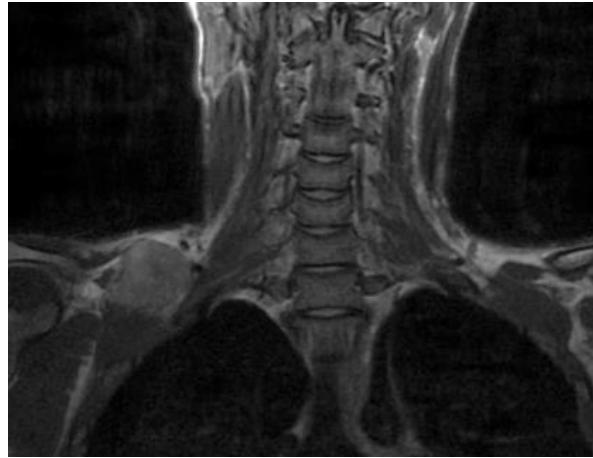
ADC map

ADC值 = $1.3 \times 10^{-3} \text{ mm}^2/\text{sec}$

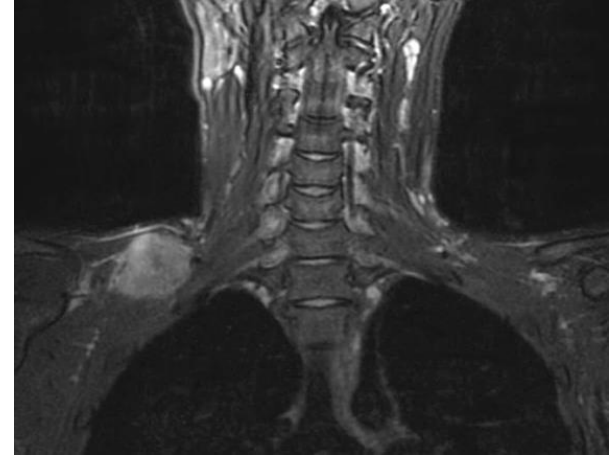
MRI



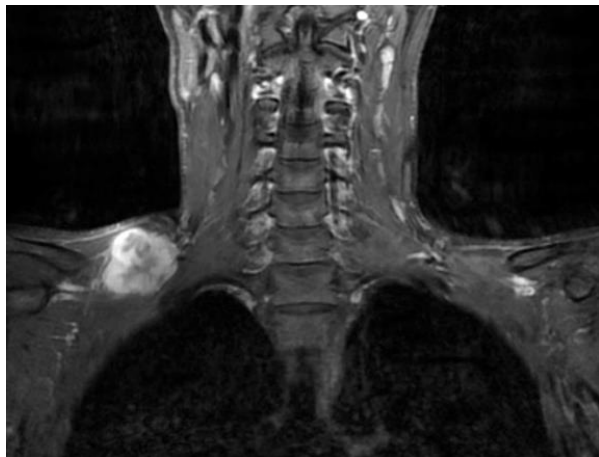
T1WI



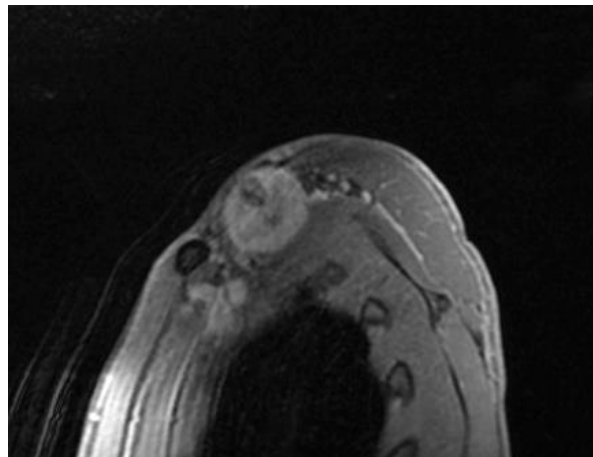
T2WI



FS-T2WI

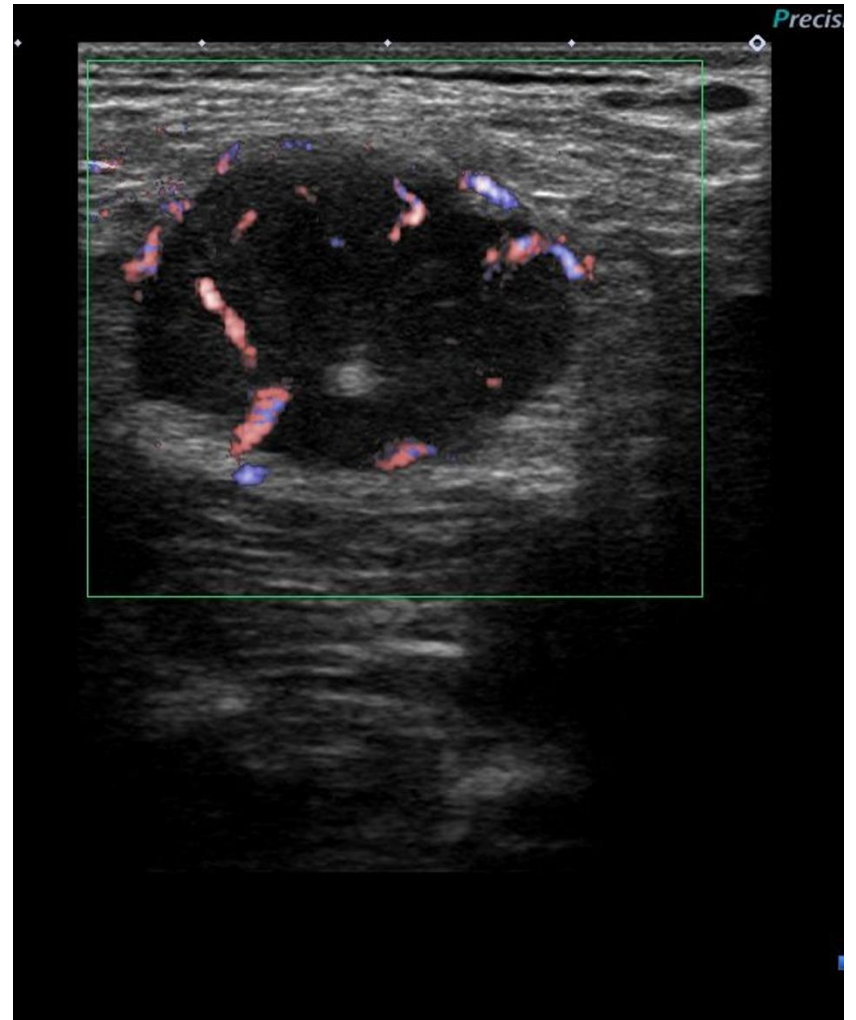
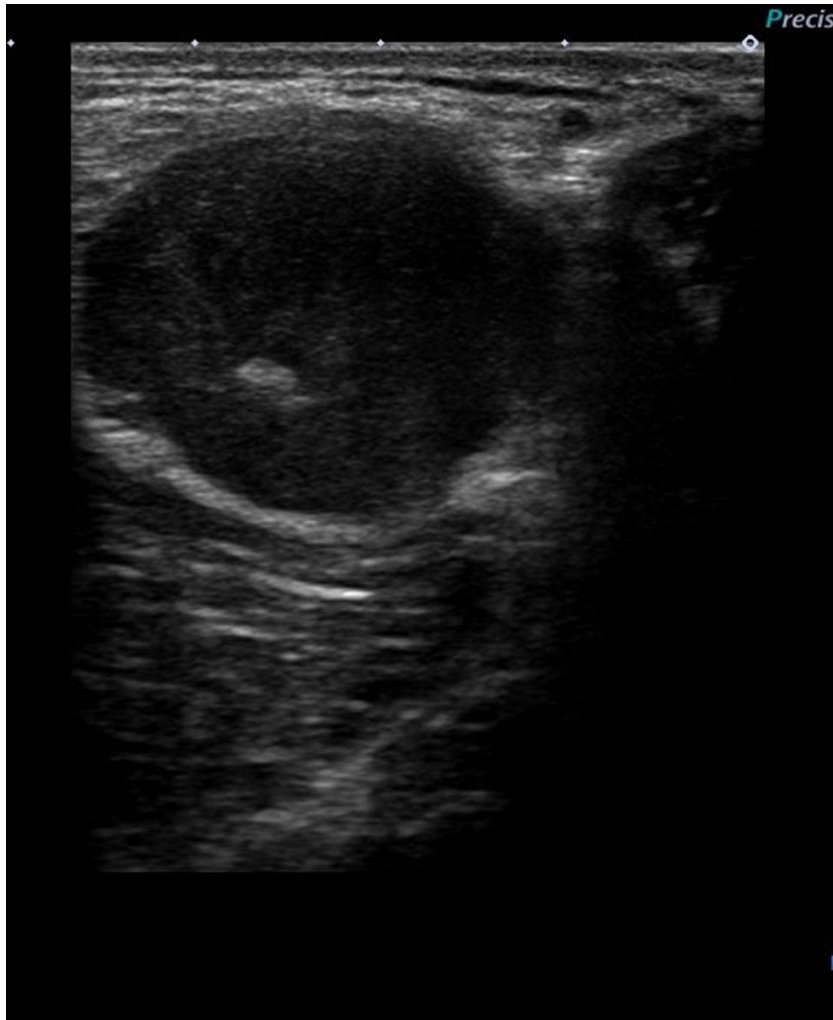

FS-Gd T1WI

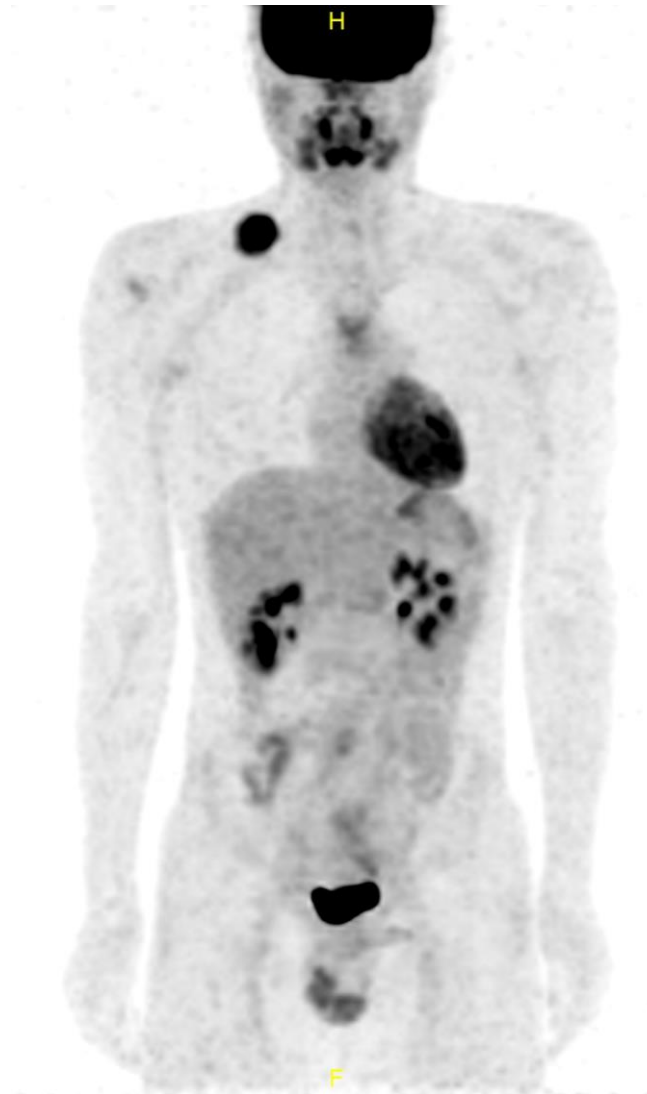

FS-Gd T1WI

US



FDG-PET



SUVmax=11